

Why did I fail?

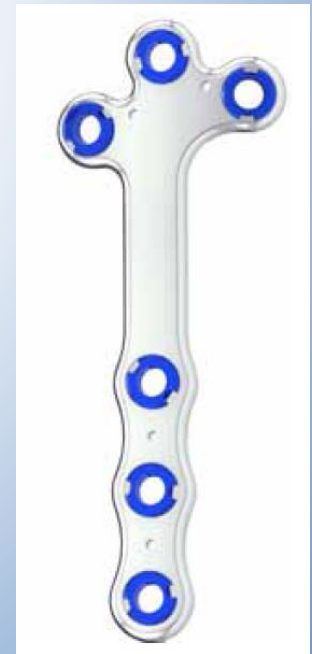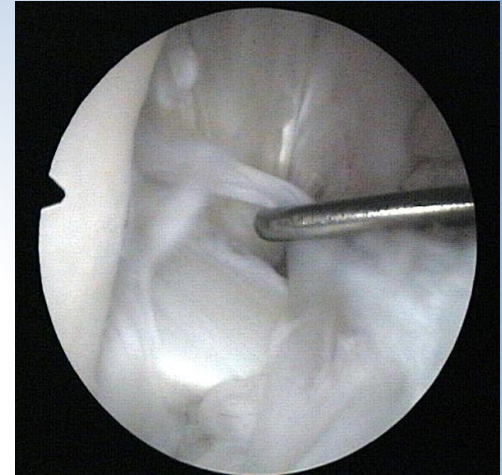S. Jauernig, DECVS

Eläinsairaala Aisti

Finland

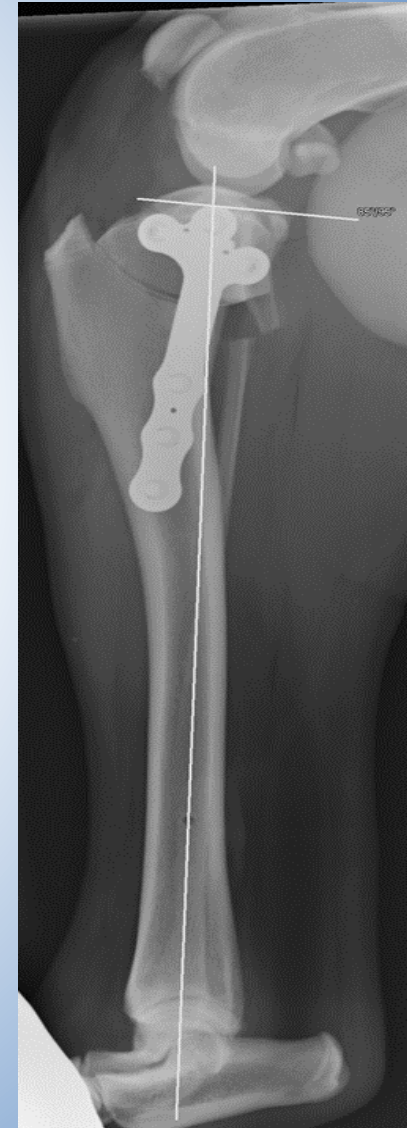
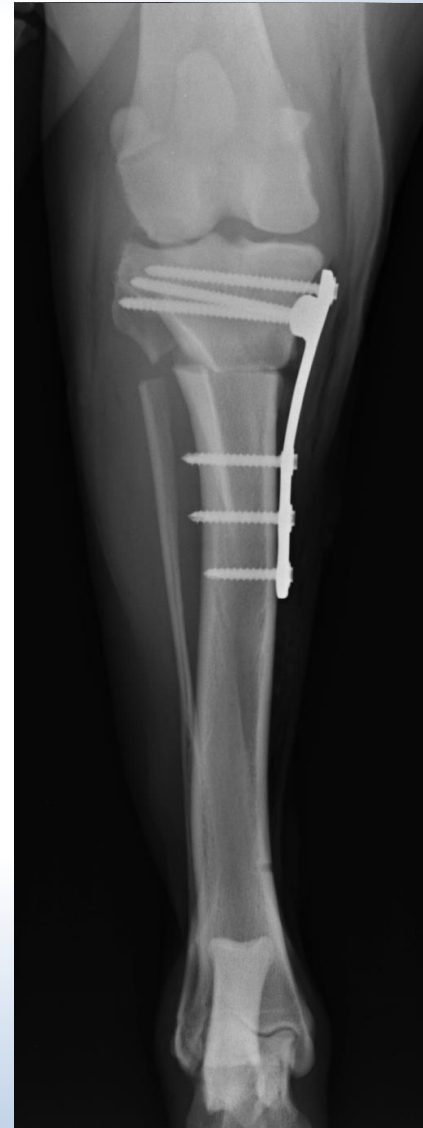Signalement

- Jetti: Great Pyrenees, male,
65 kg BW, 7 years old
- Diagnosis:
 - Cranial cruciate disease without
meniscal damage right stifle
- Therapy:
 - TPLO
 - Fixin Locking plate for large dogs (up to 85 kg BW)



Jeti: TPLO

- TPA pre-op: 25°
- TPLO:
 - Fibula osteotomy for full rotation
 - All screws coupled well
 - Dislocation of fibula fragments
 - Medial dislocation of the proximal fragment
- TPA post-op: 5°

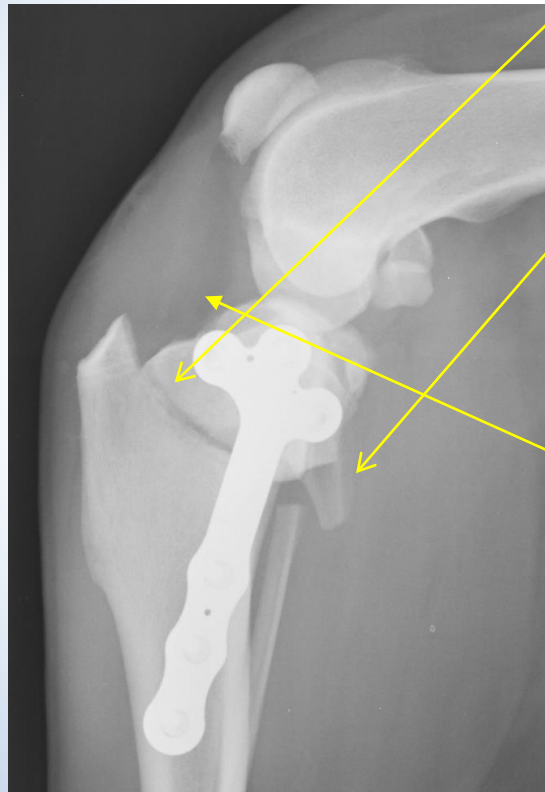
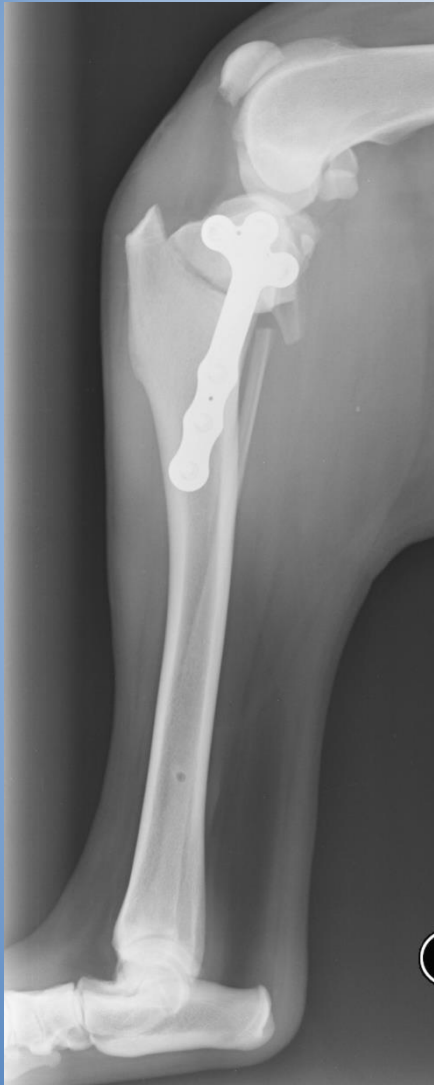

Jeti - follow up

- 1. control after 3 weeks:
 - Already good weight bearing
 - Lameness (2 of 5)
 - ROM slightly reduced in flexion
 - Not painful
 - No soft tissue swelling
 - Dog difficult to keep rested (guard dog)
- 4. week post-op:
 - Large seroma
 - Weight bearing lameness: 4 of 5
 - Leg is not positioned under the belly anymore – valgus
 - No fever, blood values normal
 - Bacteriology: negative

Jeti - follow up

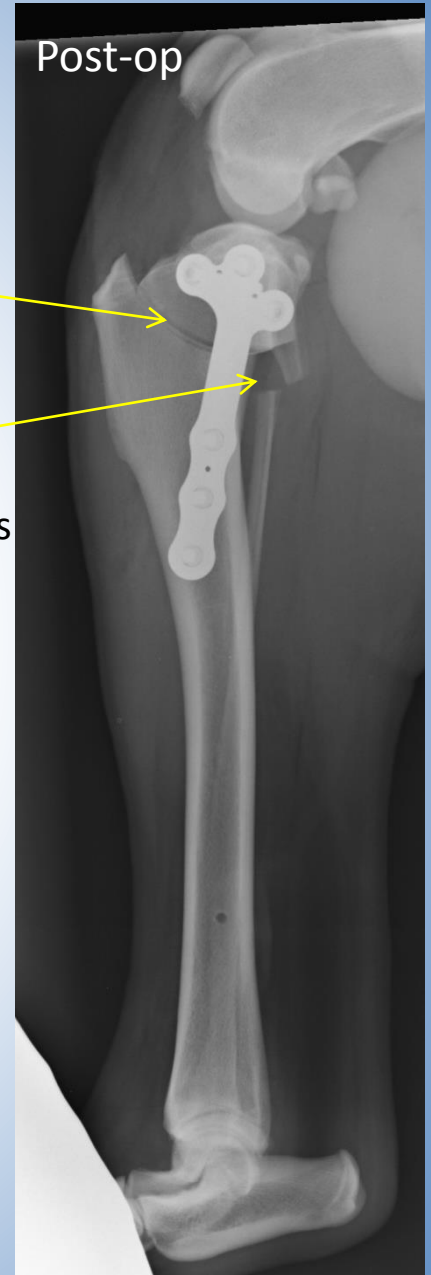- Control radiographs 4 weeks post-op



Osteotomy:
Increased gap

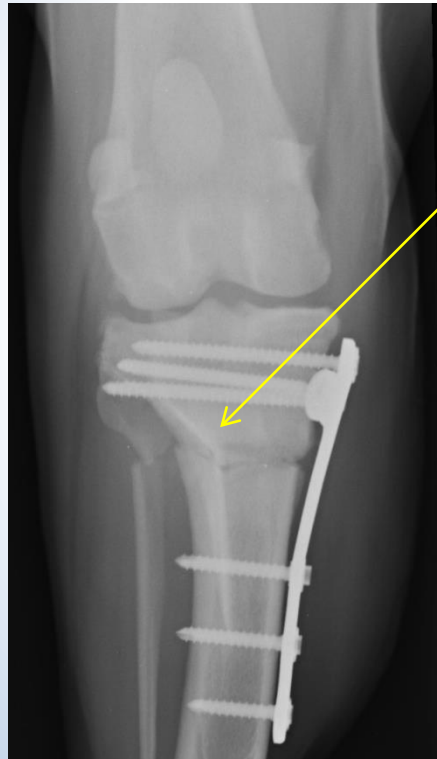
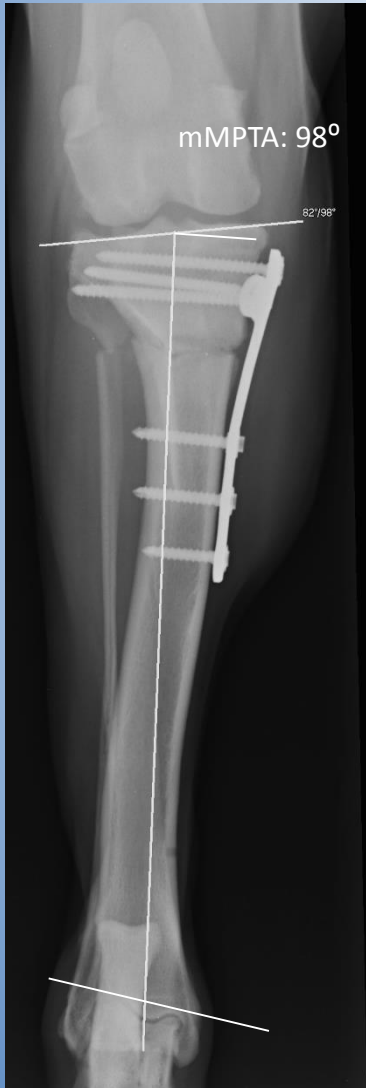Fibula:
Overriding of
fibular fragments

Thickened patella
ligament



Jeti - follow up

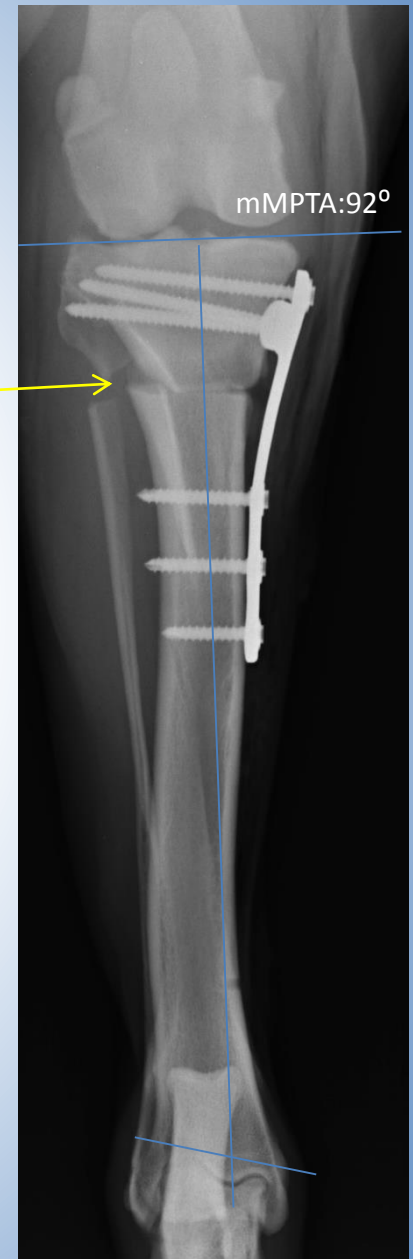- Control radiographs 4 weeks post-op



Osteotomy:
Laterally collapsed

Valgus:
mMPTA 98°

Normal range:
90-96 °

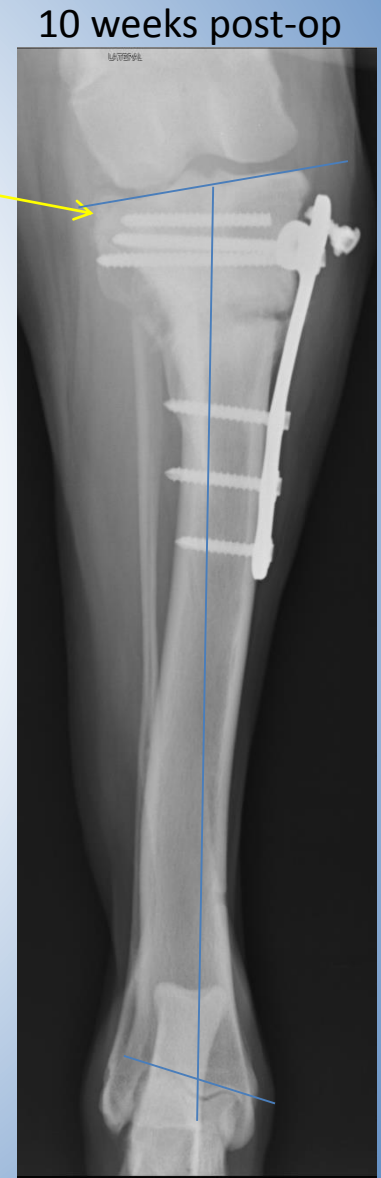
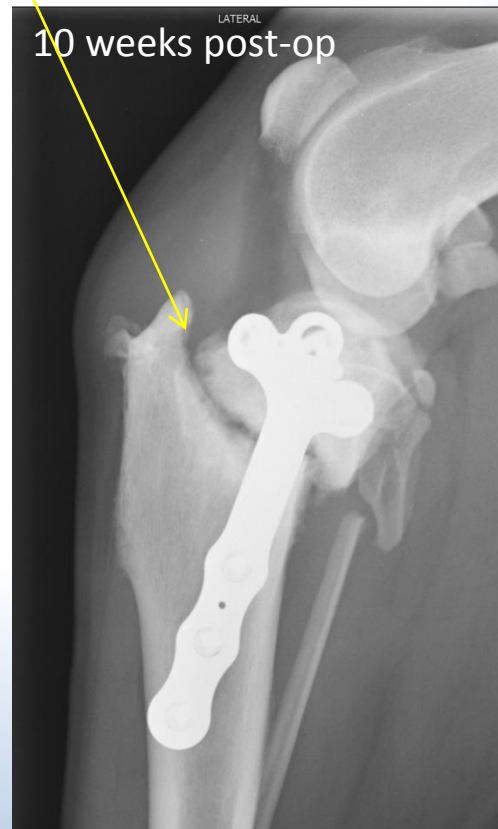
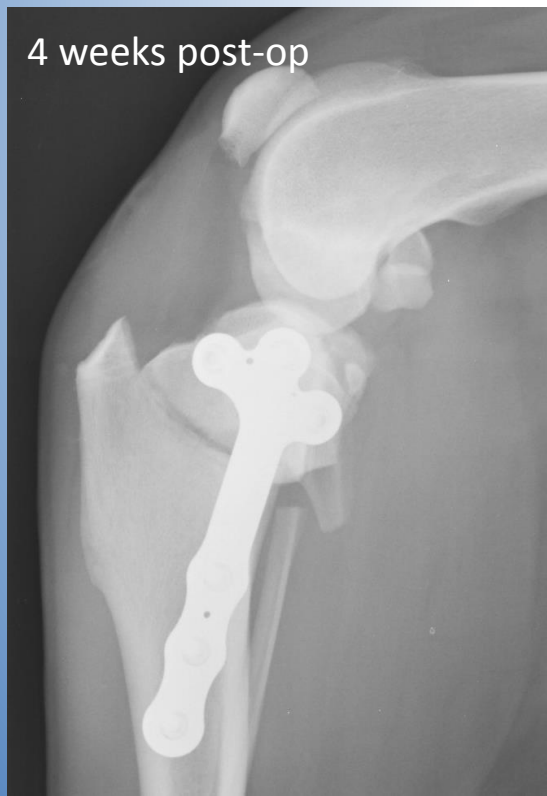Jeti - follow up 10 weeks post-op

- Orthopedic examination:
 - Weight bearing lameness 3 of 5
 - Marked soft tissue reaction above the plate
 - ROM reduced,
 - Slight pain reaction
 - Thickened patella ligament

Jeti - follow up 10 weeks post-op

- Radiographs:
 - Implant failure: caudo-proximal screw broken
 - Bone absorption osteotomy gap
 - Unchanged valgus
 - Thickened patella ligament

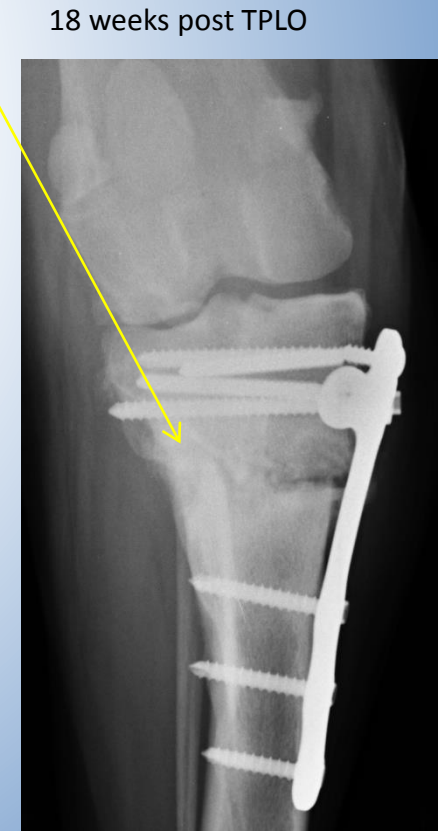
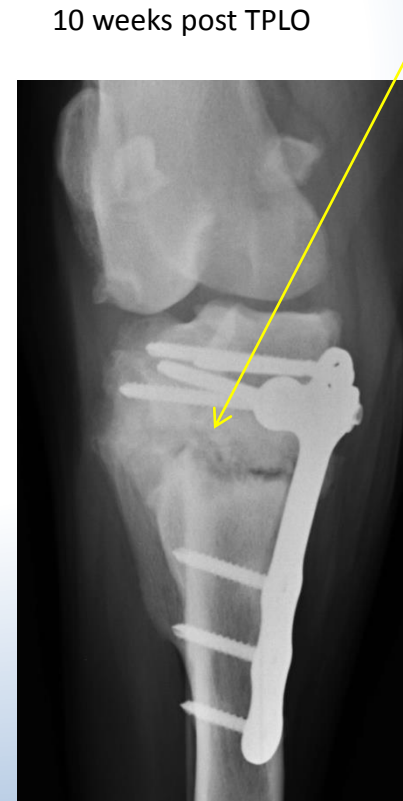
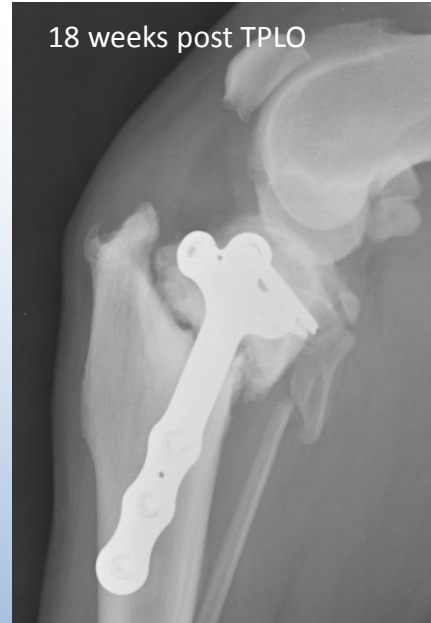
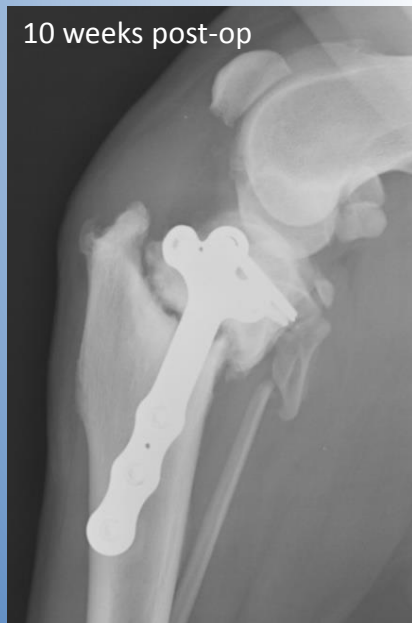Jeti – follow up

- Problems:
 - Implant failure
 - Delayed union
- Possible reasons:
 - Mechanical instability
 - Biological factors (heat)
 - Infection
- Treatment options:
 - Insertion of AO-screw
 - Autogenous cancellous bone graft
 - osteogenetic, osteoconductive, osteoinductive
 - Bone marrow aspirates (+/- synthetic ceramics)
 - rhBMP: osteoinductive
 - Additional stabilization: ESF
 - plate – insufficient space
 - pins +/- cerclage – insufficient stability

Jeti - follow up

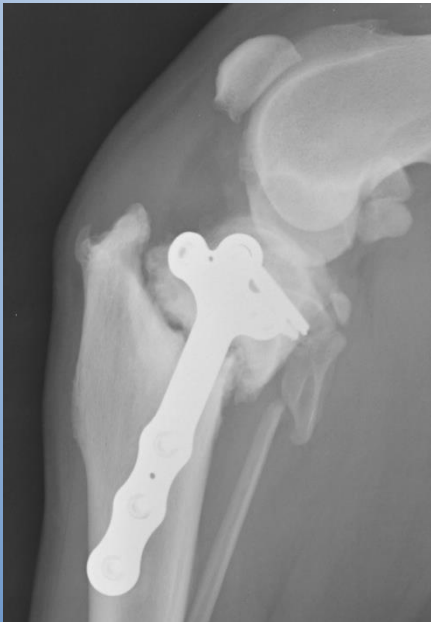- Treatment:
 - New AO-screw (12 weeks post TPLO, no further treatment wished by owner)
- Control 6 weeks after 2. OP (18 weeks after 1. operation):
 - Clinically improved but
 - Implant failure of new screw
 - Other implants and valgus unchanged
 - No bridging callus
 - Some new bone formation lateral cortex
 - Lateral smaller gap ?



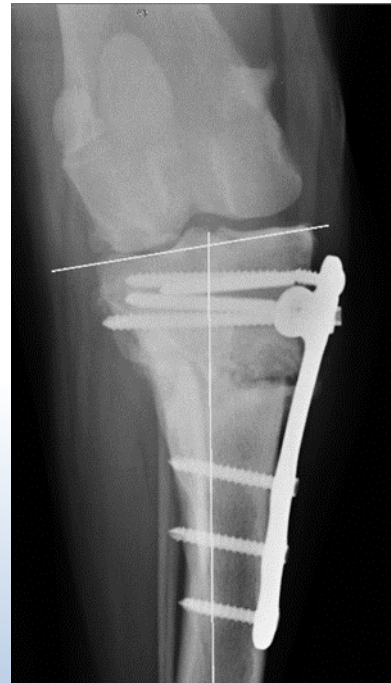Jeti - follow up

- Treatment:
 - New AO-screw (12 weeks post TPLO, no further treatment wished by owner)
- Control 6 weeks after 2. OP (18 weeks after 1. operation):
 - Clinically improved but
 - Implant failure of new screw
 - Some new bone formation lateral cortex
 - Lateral smaller gap
 - Valgus: mMPTA: 99°

18 weeks post TPLO



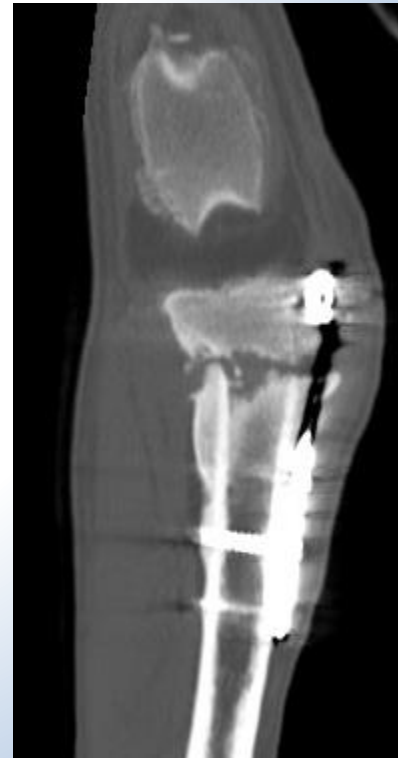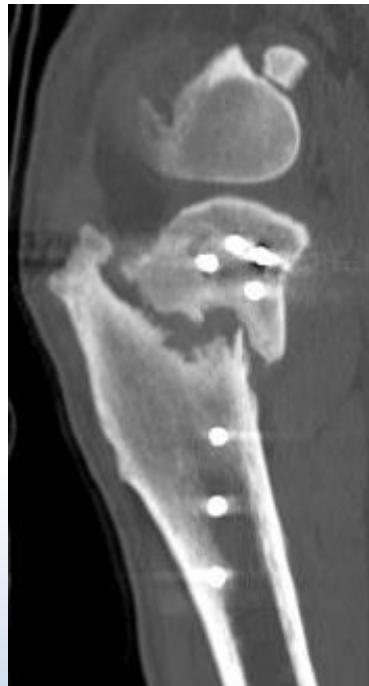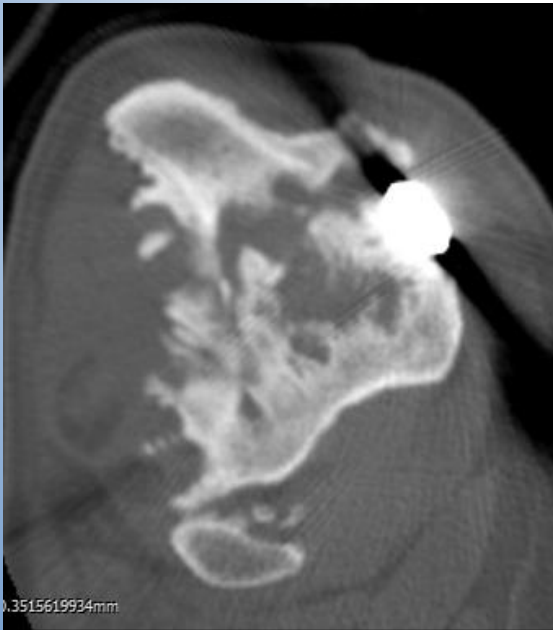
18 weeks post TPLO



mMPTA: 99°

Jeti - follow up

- CT: 7 months post TPLO
 - Non-Union
 - Minor bridging callus lateral aspect
 - Ddx: Neoplasia



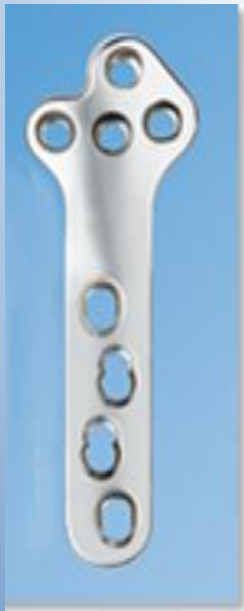Discussion

- Fibula osteotomy increased bending forces
- Instability caused Implant failure

Non-Union

Could it be prevented?

Different plate design?



4 screws proximal



Discussion

- Insertion of spongiosa with screw replacement?
- Insisting on more aggressive treatment of delayed union?
- Changing the plate –
 - only useful if new locking plate gives real improvement
 - Screw holes – loss of bone stock
 - Plate itself no sign of failure
- In meantime > 7 months post TPLO
 - Clinically dog is improved but now steady state
 - Exercise is gradually increased
- Treatment plan:
 - Aim: bridging callus formation →
 - New Synthes plate
 - + external skeletal fixateur?
 - rhBMP 2
 - Autologous cancellous bone graft ?